Treating greenstick fractures

By Russell Smith, PA

A member of the Cook Children's Orthopedic Services team

Ronald Burke, M.D. ~ David Gray, M.D. ~ Hinton Hamilton III, M.D.
Jason M. Kennedy, M.D. ~ Matthew E. Mayfield, M.D. ~ Larry Messer, M.D.
Richard Schuster, M.D. ~ Pamela J. Sherman, M.D. ~ Christopher Vara, M.D.

Between 1-2 percent of all children will sustain a fracture in any given year, and greenstick fractures are one of the most common types experienced in this population. These occur when a bone is bent beyond its limit, causing one side of the cortex to be ruptured while the other side remains intact. The radius, ulna, tibia, fibula and humerus are the bones most commonly affected. Greenstick fractures may require open or closed reduction with or without hardware. Decision for surgery depends on the age of the child, degree of angulation and the amount of visual deformity present in the limb.

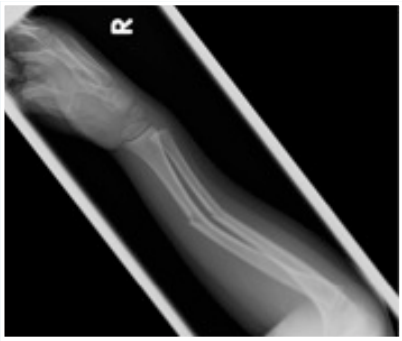

Greenstick fractures

Presentation:

- The two most common mechanisms of injury are falls and direct blows.
- Deformity may occur depending on the degree of angulation, amount of force and the patient's age.
- Swelling and discoloration may vary, but most are painful upon palpation.

Work up:

- History and physical exam may indicate pain in the affected limb, decreased and/or painful range of motion of the joints above or below, and may include obvious deformity in the affected limb.
- X-ray is usually sufficient to identify greenstick fractures.
- CT scan and MRI are rarely needed to evaluate these types of fractures.

Treatment:

- Simple cast application.
- Closed reduction with cast.
- Open reduction with percutaneous pinning.
- Time in the cast varies 3-8 weeks with fracture type.

Indications for referral:

- Angulation causing obvious physical deformity.
- Any associated injuries to surrounding tissues including joints and adjacent bones.
- Clinical suspicion by treating physician with or without X-ray confirmation of a fracture.

When to refer:

- Patient should be splinted for immobilization in the treating physician's office or referred to UCC/ED for immobilization upon identification or suspicion of a fracture.
- Patient should be seen by an orthopedic provider 3-5 days post-injury for cast application.

Options for surgery:

- Manipulation of fracture with closed reduction and cast application under sedation.
- Open repair with/without percutaneous pinning:
  - Supracondylar type 2 fractures.
  - Proximal or distal tibia fractures with significant angulation.
- Open reduction with instrumentation for older children and adolescents.

References:
Rang's Children's Fractures, 3rd edition.
Rockwood and Wilkins' Fractures in Children, 7th edition.
Wenger and Rang, The Art and Practice of Children's Orthopaedics.

CookChildren's

CookChildren's

For referrals and consultations:

Cook Children's Orthopedic Services

682-885-4405 phone

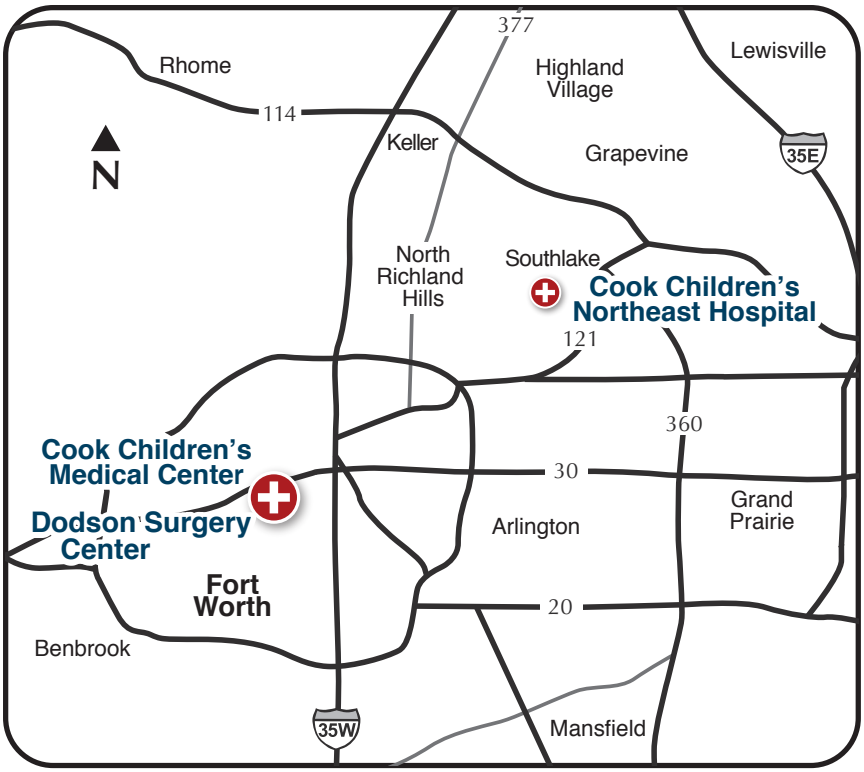

Office locations

Dodson Specialty Clinics

1500 Cooper Street
Fort Worth, TX 76104

Southwest Multi Specialty

6210 John Ryan Dr., Ste. 107
Fort Worth, TX 76132

Hurst Multi Specialty

750 Mid Cities Blvd., Ste. 100
Hurst, TX 76054

Cook Children's Urgent Care and Pediatric Specialties

2727 E. Southlake Blvd.
Southlake, TX 76092

Surgery locations

Cook Children's Medical Center
801 Seventh Ave.
Fort Worth, TX 76104

Dodson Surgery Center
1500 Cooper St.
Fort Worth, TX 76104

Cook Children's Northeast Hospital
6316 Precinct Line Rd.
Hurst, TX 76054

CookChildren's

www.cookchildrens.org